

Rapporteurs:
Ioannis Fragkioudakis, with Prof. Ioannis Vouros

Affiliation:
Postgraduate programme in periodontology,
Aristotle University of Thessaloniki, Greece

study

Resorbable membrane as adjunct to reconstructive peri-implantitis surgery

Authors:
Eric Regidor, Alberto Ortiz-Vigón, Mario Romandini, Carlotta Dionigi, Jan Derks, Mariano Sanz

Background

Peri-implantitis treatment aims at reducing inflammation and preventing peri-implant bone loss, thereby extending the lifespan of an implant. Non-surgical mechanical instrumentation has been shown to be largely inefficient, so surgical therapy is often implemented to treat peri-implant defects.

A recent study suggested that the adjunctive use of bone substitutes in reconstructive peri-implantitis therapy resulted in similar radiographic outcomes to those obtained by open-flap debridement (OFD).

The use of resorbable membranes in guided bone regeneration (GBR) has shown promising results compared with bone substitutes alone. However, it remains uncertain whether the use of a resorbable membrane, covering the bone-grafting material, would add any additional benefit in reconstructive peri-implantitis surgery.

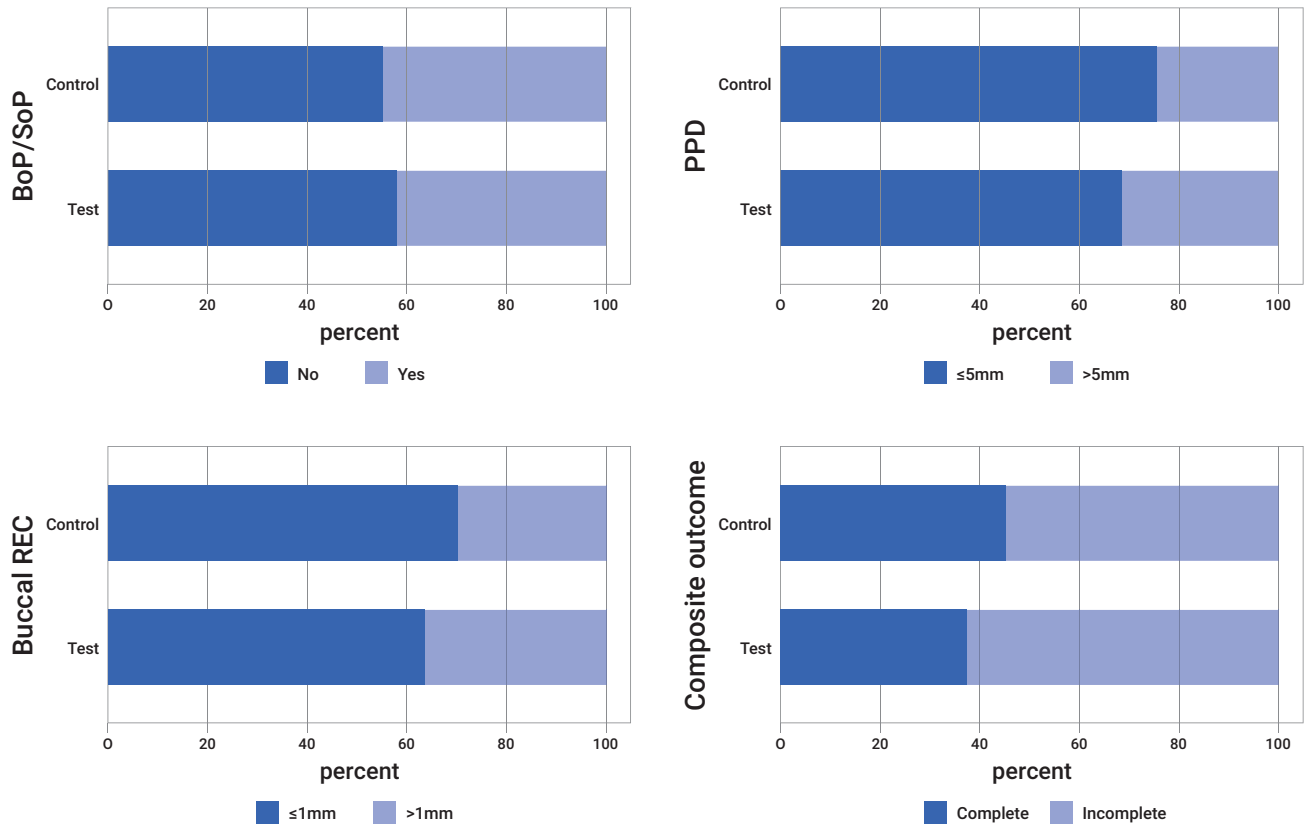
Aim

The aim of this randomised controlled trial (RCT) was to evaluate the potential benefit of using a resorbable membrane within the reconstructive surgical therapy of peri-implantitis.

Materials & methods

- The study was designed as single-centre RCT with two groups:
 - Test group: Reconstructive peri-implantitis treatment with xenogeneic bone and resorbable membrane.
 - Control group: Reconstructive peri-implantitis treatment with xenogeneic bone alone.
- Patients included were over 18 years of age, who had given signed informed consent. Patients were excluded if they presented systemic diseases or medication contraindicating oral surgery.
- Implants were diagnosed with peri-implantitis if, after one year in function, they displayed probing pocket depth (PPD) ≥ 7 mm, along with bleeding or suppuration on probing (BoP/SoP) and radiographical marginal bone loss (MBL) ≥ 3 mm. In addition, peri-implant defects were defined as presenting an intrabony component ≥ 3 mm deep and ≥ 4 mm wide and affecting at least two bone walls.
- All patients received surgical treatment four weeks after non-surgical instrumentation and oral-hygiene instructions. Full-thickness flaps were elevated, granulation tissue was removed with titanium curettes, and implant decontamination was performed with titanium brushes. All intrabony defects were filled with xenogeneic bone. Random allocation to test and control groups was performed during surgery. In the test group, the defects were covered with a resorbable collagen membrane.
- Patients were enrolled in a maintenance programme, receiving oral-hygiene instructions and professional plaque removal four weeks, six weeks, six months, and 12 months after surgery.
- The primary outcome was a composite parameter assessed at 12 months:
 - Implant not lost.
 - Absence of BoP/SoP at all sites.
 - PPD ≤ 5 mm at all sites.
 - Change of buccal marginal mucosal level (buccal REC) ≤ 1 mm.
- The secondary outcomes, also evaluated at 12 months, were:
 - Changes in PPD, BoP, SoP, keratinised mucosa width (KMW), buccal REC, and MBL.
 - Patient-reported outcomes.
- The duration of the surgical intervention and the occurrence of post-operative complications and adverse events were also assessed.

Figure: Composite primary outcome, 12 months



Results

- The study included 43 patients (test, 21; control, 22) at baseline; 39 patients (test, 19; control, 20) completed the 12-month trial.
- At 12 months, no implants were lost, and all criteria of the primary composite outcome were met in 45.0% of implants in the control group and 36.8% of implants in the test group, with no statistical difference between groups.
- Buccal REC and KMW changes and bone gain (MBL change) were similar between the two groups.
- Patients in the test group presented higher pain scores two weeks after treatment.
- Complications related to the surgical interventions were noted only in the test group.
- Treatment duration in the test group was slightly longer than in the control group.
- Overall satisfaction with aesthetics was high for both groups at 12 months.

Limitations

- The study population was small, which limits the statistical power of the study.
- The distribution of defect types at baseline was not equal between the two groups (there were more non-contained defects in the test group).
- The study examined the use of only one type of graft – a xenogeneic bone graft – and used a non-submerged protocol.

Conclusions & impact

- The use of a resorbable membrane in reconstructive peri-implantitis surgery with xenogeneic bone did not have further clinical or radiographic benefits, compared to the use of the graft alone, 12 months after treatment.
- A higher rate of post-operative complications and post-surgical pain, as well as longer surgical time, were observed when a membrane was used.

JCP Digest 114, published in June 2023, is a summary of 'The adjunctive effect of a resorbable membrane to a xenogeneic bone replacement graft in the reconstructive surgical therapy of peri-implantitis: A randomized clinical trial.' *J Clin Periodontol.* 2023; 50(6):765-783. DOI: 10.1111/jcpe.13796

<https://www.onlinelibrary.wiley.com/doi/10.1111/jcpe.13796>

Access through EFP members' page log-in: <http://efp.org/members/jcp.php>